

REVIEW

Estimation of age in the living: in matters civil and criminal

Anil Aggrawal

Maulana Azad Medical College, New Delhi, India

Abstract

Estimation of age is one of the main tasks of a forensic practitioner, especially in third world countries, where many births take place in rural settings without the benefit of the expert supervision of a trained obstetrician. Such births are poorly recorded or more often not recorded at all in terms of exact dates. In many other cases, records are fraudulently falsified for some gain, e.g. to get government jobs or pensions. Developed countries, where ordinarily the birth records are meticulously maintained, are not immune to this problem either. Estimation of the age of living individuals may be needed here for refugees or other persons who arrive without acceptable identification papers. A wide variety of methods are used by the forensic clinician to assess the age of the individual in such cases. This paper discusses and evaluates the most common methods used in India, although the methods can be effectively utilized by medico-legal professionals anywhere in the world.

Key words age estimation; deciduous teeth; odontological examination; ossification of bones; permanent teeth; radiological examination; successional teeth; superadded teeth; third molar; wisdom tooth.

Introduction

Estimation of the age of an individual may become necessary in a number of cases and virtually no age is immune from medico-legal scrutiny. In the author's 30 years of practice, children as young as 4 years have been brought for medico-legal examination of age. In these circumstances the issue in question is whether the child has attained 5 years of age. This relates to Section 6 (a) of The Hindu Minority and Guardianship Act 1956, where a minor who has not reached the age of 5 years shall ordinarily be retained in the custody of the mother, and a divorced mother often wants to keep the child in her custody. At the other end of the spectrum, people as old as 75 years of age (allegedly) have come for a medico-legal opinion. Many allege that they are over 70 years of age in order to qualify for State Government pension schemes for the elderly. Thus virtually no age is irrelevant from a medico-legal point of view.

Ages of medico-legal importance

Almost every age is important from a medico-legal perspective. The examples in this paper give only a glimpse

of the full range of ages which a practising medicolegist may be asked give an opinion on. This list will differ from country to country and even within the various states of the same country. It would be helpful for a medicolegist of a particular state or country to compile his/her own list in accordance with his/her own laws. As an illustration, some examples of each age of medico-legal importance are given here but an exhaustive list of various ages which are important from a medico-legal angle is available elsewhere (Aggrawal, 2000).

Medico-legal importance of 5 years of age

According to Section 6 (a) of *The Hindu Minority and Guardianship Act 1956*, a minor who has not over the age of 5 years shall ordinarily be retained in the custody of its mother.

Medico-legal importance of 7 years of age

According to Section 82 of the Indian Penal Code (I.P.C.), a child less than 7 years of age cannot commit an offence.

Medico-legal importance of 10 years of age

According to Indian Customs rules, free allowance for tourists of Indian origin is Indian Rupees (INR) 25 000 per passenger, including 2 L of whisky/wine and 200 cigarettes. However, this free allowance is lower for passengers less than 10 years of age (Fig. 1).

Correspondence

Professor Anil Aggrawal, Maulana Azad Medical College, Department of Forensic Medicine, S-299, Greater Kailash-1, New Delhi-110048, India. T: +91 11 29235460; E: anil.aggrawal@gmail.com

Accepted for publication 29 December 2008

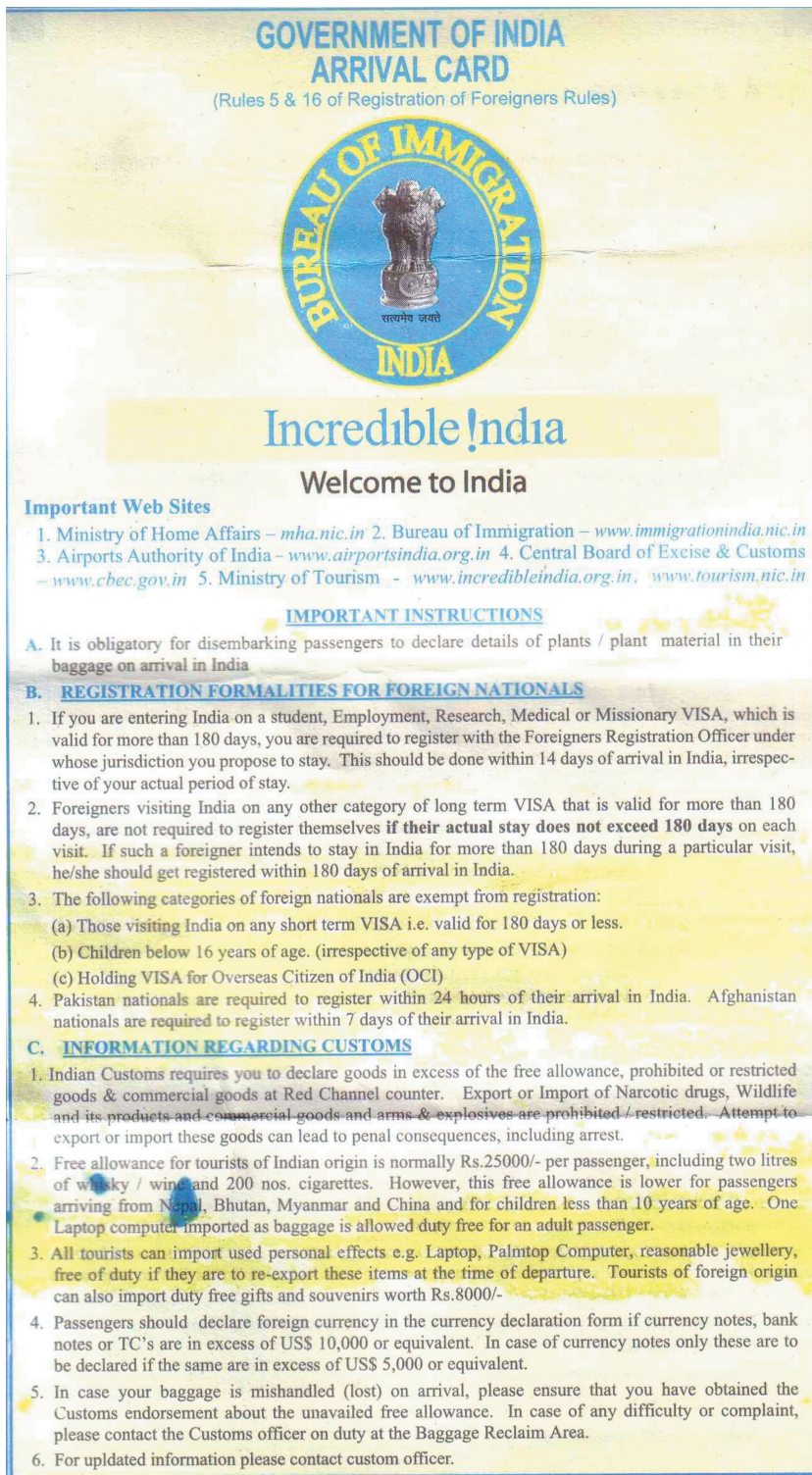


Fig. 1 Government of India arrival card, which all overseas tourists arriving in India, and Indians returning back to India, have to complete. Please see rule 2 in section C.

Medico-legal importance of 12 years of age

According to Section 83 of I.P.C., the crime committed by a child between 7 and 12 years of age is not an offence if he has not attained sufficient maturity of understanding. The judge often decides this issue.

Medico-legal importance of 13 years of age

According to Section 375 of I.P.C. (local amendment by Manipur Government), sexual intercourse with one's own wife, even with her consent, is rape if she is younger than 13 years. This provision is for the state of Manipur only by

a local amendment. For the rest of the country this age is 15 years.

Medico-legal importance of 14 years of age

According to Article 24 of The Indian Constitution, a child below 14 years shall not be employed to work in any factory or mine or engaged in other hazardous employment (same provisions are reproduced in Section 67 of The Indian Factories Act 1948).

Medico-legal importance of 15 years of age

According to *Indian Factories Act 1948*, a child above 15 years and below 18 years is an adolescent. A 'child' is a person who has not yet attained 15 years. A 'young person' may encompass either a child or adolescent.

Medico-legal importance of 16 years of age

According to section 361 of I.P.C., whoever takes or entices any minor under 16 years of age if a male (or under 18 years of age if a female, or any person of unsound mind) out of the keeping of the lawful guardian of such minor (or person of unsound mind) without the consent of such guardian, is said to kidnap such a minor (or persons) from lawful guardianship.

Medico-legal importance of 18 years of age

Under section 5 (iii) of *Hindu Marriage Act 1955*, the age for marriage for a girl is 18 years. If a girl marries before this age, the punishment is prescribed in section 18 (a) of the same act. It is simple imprisonment which may extend to 15 days, or a fine which of up to 1000 Indian Rupees (INR), or both. The marriage is not dissolved.

Medico-legal importance of 20 years of age

Section 293 I.P.C. states that if a person sells, lets to hire, distributes, exhibits or circulates obscene objects to any person under 20 years of age, then on first conviction, he/she would be sentenced to an imprisonment of 3 years and a fine of 2000 Indian Rupees (INR). On second conviction, the punishment would be 7 years and a fine of 5000 Indian Rupees (INR).

Medico-legal importance of 21 years of age

Under section 5 (iii) of *Hindu Marriage Act 1955*, the age for marriage for a boy is 21 years. If a boy marries before this age, the punishment is prescribed in section 18 (a) of the same act. It is simple imprisonment of up to 15 days, or a fine which of up to 1000 Indian Rupees (INR), or both. The marriage is not dissolved.

Medico-legal importance of 25 years of age

According to Article 84 (b) of The Constitution of India, the minimum age for contesting for the membership of Parliament is 25 years.

Medico-legal importance of 30 years of age

According to Article 84 (b) of The Constitution of India, this is the minimum age for election to the Council of States (*Rajya Sabha*).

Medico-legal importance of 35 years of age

According to Article 58 (1)(b) of The Constitution of India, this is the minimum age for appointment as the President of India.

Medico-legal importance of 60 years of age

This is age of retirement from Government service in several countries including India.

Medico-legal importance of 65 years of age

According to Section 10 (2) of the *Consumer Protection Act 1986*, every member of the District Forum shall hold office for a term of 5 years or up to the age of 65 years, whichever is earlier, and shall not be eligible for reappointment. District Forum is a form of civil court which delivers judgments in cases of consumer grievances. Similarly, the State Commission and the National Commission (mentioned below) are also akin to civil courts, which are higher in rank than the District Forum.

Medico-legal importance of 67 years of age

According to Section 16 (3) of the *Consumer Protection Act 1986*, every member of the State Commission shall be below 67 years of age.

Medico-legal importance of 70 years of age

According to Section 20 (3) of the *Consumer Protection Act 1986*, every member of the National Commission shall be below 70 years of age.

Although no age is immune from the medicolegists' scrutiny, about 90% of their work falls within the age range of 10–20 years. This is fortunate, because this is the age range which can be most accurately estimated.

Methods of age estimation in the living

As the human body ages, biological changes occur, many of which are measurable. Thus as a child matures, height

and weight are gained, bones begin to ossify, teeth erupt and secondary sex characters appear. Many of these changes are too variable to be of any reliable use for the estimation of age (e.g. height and weight), but others are fairly constant, and these have been employed by medico-legal workers for the estimation of age. The most important are (1) eruption of teeth (both primary and secondary), (2) ossification of bones and (3) secondary sex characters (Aggrawal & Busuttill, 1991). As mentioned earlier, the determination of age is much more accurate in the earlier years of life, up to around 20 years. In this author's experience, the accuracy declines drastically after this age.

Teeth

Tooth development

The alveolar crypts which contain the developing teeth are formed around the 4th month of intrauterine life. Development of the tooth begins with the formation of the cellular tooth germ within the alveolar bone, in the shape of the crown. The deciduous teeth begin to mineralize at about 13–20 weeks of intrauterine life, and by 28 weeks, all of the deciduous teeth have commenced mineralization (Cameron & Sims, 1974). The anterior buccal cusp of the lower first permanent molar begins to mineralize a week or two before birth. Thus at birth the rudiments of all the temporary teeth and of the first permanent molars may be found in the jaws.

Two sets of teeth

There are two sets of teeth – temporary (also known as deciduous or milk teeth) and permanent. During childhood the temporary set erupts. By the age of 2½–3 years, the temporary set is complete. At around the age of 6, the first permanent tooth – the first molar – erupts. Gradually the permanent set replaces the temporary set. The last permanent tooth to erupt is the third molar, also known as the wisdom tooth, which may erupt sometime between 18 and 25 years of age.

There are 20 temporary teeth – 2 incisors, 1 canine and 2 molars in each quadrant of the jaw – and 32 permanent teeth – 2 incisors, 1 canine, 2 premolars and 3 molars in each quadrant.

Temporary teeth

It is important to know the ages of eruption of both temporary and permanent teeth. Before proceeding further, it is important to bear in mind that in general, the lower (mandibular) teeth appear earlier, both in temporary and permanent teeth. There are some important exceptions, as we shall see shortly.

The ages of eruption of temporary teeth, with a few weeks' variation on either side, are summarized in Table 1.

Unless otherwise indicated, these ages are true for the upper (maxillary) teeth. Mandibular teeth appear a few

Table 1 Approximate ages of eruption of temporary teeth

Tooth	Age of eruption
Lower central incisor	6 months
Upper central incisor	8 months
Upper lateral incisor	10 months
Lower lateral incisor	12 months
First molar	14 months
Canine	18 months
Second molar	24–30 months

Table 2 Approximate ages of eruption of permanent teeth

Tooth	Age of eruption
Molar, 1st	6 years
Incisors, central	7 years
Incisors, lateral	8 years
Premolar, 1st	9 years
Premolar, 2nd	10 years
Canine	11 years
Molar, 2nd	12 years
Molar, 3rd	18–24 years

weeks earlier. The exception mentioned earlier occurs in the case of lateral incisors, which appear earlier in the upper jaw (as a rule of the thumb, lower teeth always appear first).

Permanent teeth

The order of appearance of permanent teeth, with a few months' variation on either side, is given in Table 2. It is important to appreciate that the dates of eruption of both temporary and permanent teeth cannot be regarded as absolute as they are subject not only to individual variation but also to populational and environmental influences. Thus it is very important that medico-legal workers first gather data regarding dental eruption in their own region, and then apply that data to their medico-legal work.

These eruption ages are true for maxillary teeth. Generally speaking, the mandibular teeth would appear a few months earlier. The major exception is in the case of canines, which appear almost 2 years earlier. Thus the lower canine would appear around 9 years.

Premolars are an exception in the sense that they appear earlier in the upper jaw. Thus the lower first premolar would appear at around 10 years, and the lower second premolar would appear at around 11 years.

The whole subject of dental eruption, especially that of the permanent dentition, may sound complex, but it can be remembered using a simple mnemonic: *Mama is in pain; papa can make medicine*. The first letter of each word indicates the first letter of the maxillary tooth. The mnemonic can be decoded as shown in Table 3.

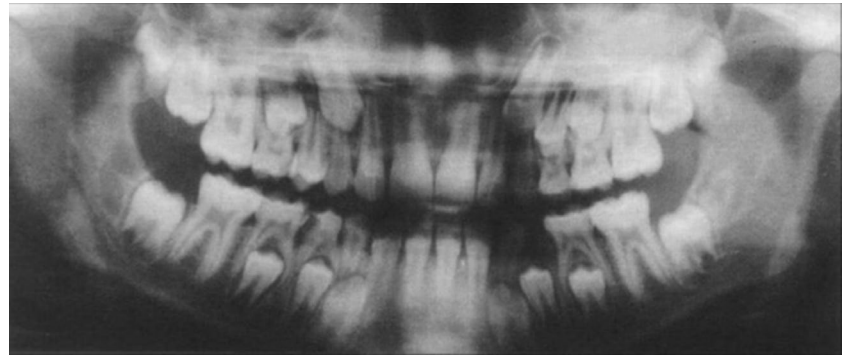


Fig. 2 Panorex view of a child between 8 and 9 years.

Table 3 A simple mnemonic to remember the ages of eruption of permanent teeth

Mama	Molar, 1st
Is	Incisor, 1st
In	Incisor, 2nd
Pain	Premolar, 1st
Papa	Premolar, 2nd
Can	Canine
Make	Molar, 2nd
Medicine	Molar, 3rd

The stage of mixed dentition

Before the age of 6 years (when the first permanent molar appears), all the teeth in a child's mouth are deciduous. After the age of 12 years (when the second permanent molar appears), all the teeth are permanent. Between the ages of 6 and 11, some teeth are deciduous and some are permanent, i.e. the individual is represented by a mixed dentition. It can be rather tricky to examine a child in this age group as one must differentiate between the temporary and the permanent teeth. A few pointers could be helpful. The deciduous teeth are usually whiter and the enamel is less transparent than that of the permanent teeth. This is usually described by saying that 'deciduous teeth are china-white in colour, whereas permanent teeth are ivory-white in colour'. The deciduous teeth are in most dimensions smaller than the permanent teeth. However, deciduous molars are wider mesiodistally than the permanent premolars which will take their place (Brand & Isselhard, 1986). Crowns of deciduous teeth are more bulbous and the cusps are more pointed when the teeth first erupt (Rogers, 1988). Deciduous teeth have shorter crowns with respect to their roots. The crowns have a marked constriction at the cervix, appearing as if they are being squeezed with a rubber band (Woelfel & Scheid, 1997). The enamel seems to bulge close to the cervical line, rather than gradually tapering (Osborn, 1981). Usually there are no depressions or perikymata on the labial surface of the crowns of the deciduous incisors. These surfaces are smooth. Incisal edges of the deciduous

teeth generally show no pits, whereas those of permanent show these pits (mamelons).

Many other differences are described, but they cannot be elicited clinically. For instance, it is suggested that pulp chambers are relatively larger in deciduous teeth and that the pulp horns extend rather high, placing them much closer to the enamel than in the permanent teeth (Brand & Isselhard, 1986). In case of doubt, it is best to have a panorex view of the teeth taken (Fig. 2); this can immediately show all the permanent and deciduous teeth of the mouth – erupted and unerupted. This is a relatively new method of taking dental radiographs (Mason & Bourne, 1998). Originally this was called the orthopantomograph, and the derivation OPG derived from this term is still in common use. The more modern name is dental panoramic tomograph (DPT). Many specialists like to call it by the simpler name – Panorex view. An example is shown in Fig. 2. This subject, whose age was later determined to be between 8 and 9 years, was brought to the author for age estimation, as he had stolen some valuables from a lady, and his lawyer had claimed a children's jail sentence on account of his young age. Figure 3 is a line diagram drawn from the same X-ray plate depicting some salient features of the teeth. In general, if one can see a tooth below another, obviously the one visible in the mouth is the deciduous tooth (the tooth below is the permanent tooth waiting to erupt). If no tooth is present below a tooth, that tooth has to be the permanent tooth, unless there is agenesis of the permanent tooth.

On clinical examination of this child the first permanent molar was visible but not the second permanent molar, enabling one to say that the subject was between 6 and 12 years of age. Further narrowing of the age could be done with the help of this X-ray. Both permanent incisors have erupted, but not the first premolar. These findings could enable the author to say that the child was most likely between 8 and 9 years of age.

An interesting fact to keep in mind is that the total number of teeth in a child's mouth only changes when the superadded teeth (the molars) erupt. The permanent molars erupt in a fairly regular mathematical rhythm of approximately 6, 12, and 18–24 years. Thus the total number of teeth would change only at these ages. In short,

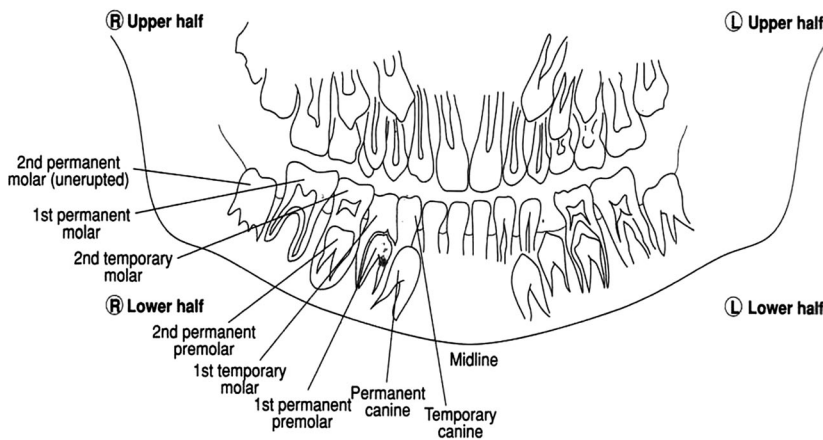


Fig. 3 A line diagram of the same X-ray. Note that permanent incisors have erupted (there are no teeth below them), but the premolars and canines have not erupted.

Table 4 The total number of teeth at various different ages. Age in most cases could be stated by simply counting the total number of teeth (NB It is tacitly assumed that there are no morphological anomalies, or no surgical interference with the teeth, such as extractions)

Age	Total number of teeth
3–5 years	20
6–11 years	24 (addition of first molar in each quadrant)
12–17 years	28 (addition of second molar in each quadrant)
Above 18 years	32 (addition of third molar in each quadrant) or possibly 24

the total number of teeth in a child’s mouth would be as shown in Tables 4 and 5.

Ossification of bones

Ossification of bones provides a very useful method of estimation of age in the living. Most bones develop either from cartilage or from fibro-membranous structures. Different bones begin and complete their ossification at different but relatively fixed periods of life. These changes can be studied by X-rays and thus provide the medico-legal specialist with a potentially powerful tool. It is useful to bear in mind a few facts before proceeding further. First,

the ages referred to must be considered as a range of possibilities as they are heavily influenced by dietetic, hereditary and geographic factors. Secondly, the ossification takes place slightly earlier (by at least 1 year) in females compared to males. An important exception is skull sutures, which obliterate earlier in males than in females. And lastly, ossification is seen earlier in tropical than in temperate climates. Unless otherwise stated, the ages mentioned here refer to Indian males.

The range of ages at which various bones commence and complete fusion is sufficiently complex and confusing as to deter a beginner from taking any substantial interest in this field of study. But fortunately a few simple rules can be useful. Figure 4 illustrates a simple way to memorize the general pattern of epiphyseal fusion in the long bones of the limbs. Imagine a person reclining on a sandy beach as shown in the diagram. His elbows are sinking in the sand. Now draw four lines parallel to the horizontal plane: the lowest one passes through the elbow; the next one through the hip and ankle joints; the next one through the shoulder and knee joint; and the uppermost passes through the wrist joint. We would expect the epiphyses around the elbow joint to complete fusion by 16 years, the epiphyses around the hip and ankle joints by 17 years, the epiphyses around the shoulder and knee by 18 years and the epiphyses around the wrist by 19 years.

Table 5 A comprehensive table showing the relative number of temporary and permanent teeth at various ages

Age in years	Temporary teeth	Permanent teeth	Total teeth	Eruption of	Fall of
5	20	0	20	none	None
6	20	4	24	Permanent first molar	None
7	16	8	24	Permanent first incisor	Temporary first incisor
8	12	12	24	Permanent second incisor	Temporary second incisor
9	8	16	24	Permanent first premolar	Temporary first molar
10	4	20	24	Permanent second premolar	Temporary second molar
11	0	24	24	Permanent canine	Temporary canine
12	0	28	28	Permanent second molar	None
18–24	0	32	32	Permanent third molar	None

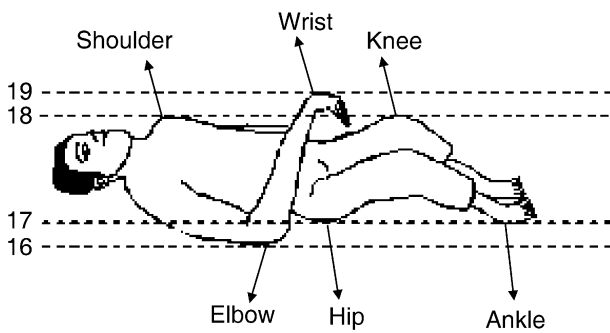


Fig. 4 A useful way to remember ages of epiphyseal union of some major bones.

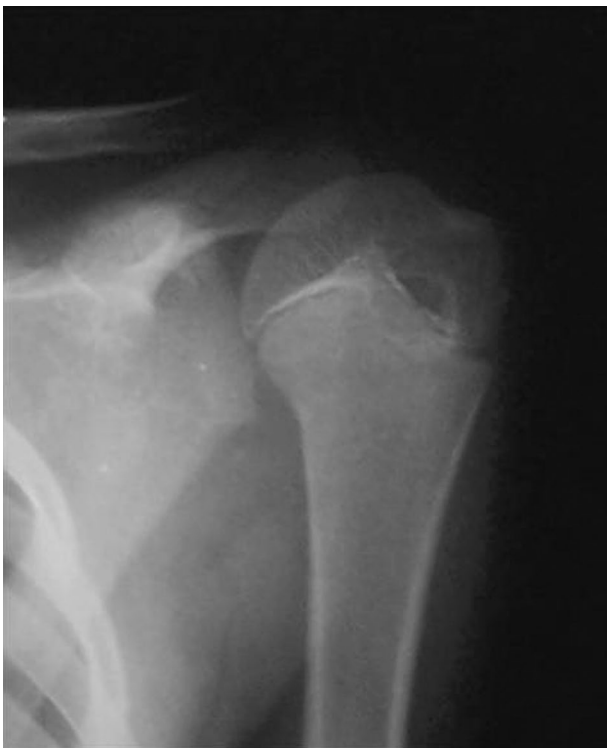

Fig. 5 AP view of the right shoulder joint in a subject between 8 and 9 years old.

It must, however, be stressed that this is a very general rule and its main utility is that it helps one to readily assign a joint to a particular age category. Several important exceptions exist which must be borne in mind.

Ossification around shoulder joint

The centre for the head of humerus appears during the first year of life, for the greater tubercle during the second year and for lesser tubercle by 5 years. The three centres unite to form a compound epiphysis by 6 years, which unites with the shaft at 13–17 years in females and at 16–20 years in males (refer to Fig. 5). The coracoid and acromion both ossify from separate centres, which are readily visible on

radiographs. The centre for the tip of coracoid process appears by about 13 years and unites by 20 years. The centre at the tip of acromion appears around 15 years and unites between 18 and 20 years.

The clavicle commences ossification before any other bone in the body (Williams & Warwick, 1980). Two centres appear in the shaft between the 5th and 6th weeks of intrauterine life, and fuse around week 7. The secondary centre appears for the sternal end after 12 years and unites with the shaft by 30 years. This is the usual figure accepted by Indian medico-legal practitioners. However, it is useful to remember that the variation here can be quite large. Jit & Kulkarni (1976) in one of the largest studies of its kind, after having studied the sternal epiphyses in 684 Indian *Punjabees*, came to the conclusion that the sternal end appeared at 11–19 years and united at 18–25 years.

Figure 5 is an AP view of the shoulder joint of the same subject whose panorex view we saw earlier. The head of the humerus, lesser tubercle and the greater tubercle have united (age > 6 years), but they have not united with the shaft (< 18 years). The centres for the tip of acromion (< 15 years) and the tip of coracoid (< 11 years) have not appeared. The sternal end of clavicle has not appeared (< 19 years). So by examining just this X-ray, one could confidently say that the age of the subject was between 6 and 11 years. The actual age of the subject was 8.5 years.

Ossification around the elbow joint

The ossification of the lower end of the humerus is more complex than that at its upper end. Four different centres of ossification appear here. The first centre to appear is in the capitulum, which appears in the second year, followed by the medial epicondyle at 4–7 years, the trochlea at around 8–9 years and the lateral epicondyle at around 10–12 years. The centres for the capitulum, trochlea and lateral condyle unite to form a conjoint epiphysis at around 12 years, which unites with the shaft at between 11 and 15 years in females and 12 and 17 years in males. The medial epicondyle joins the shaft separately at between 13 and 16 years. The head of the radius appears by year 5 and that of the ulna between 8 and 10 years. Both unite with the shaft at 12–14 years in females and 13–16 years in males.

Figure 6 is the AP view of the left elbow joint of a male who had killed a person and had applied for immunity under section 83 of the Indian Penal Code. He sought an estimate of age less than 12 years. In the X-ray all four centres (medial epicondyle, capitulum, trochlea and lateral epicondyle) can be seen separately, indicating the age is most likely to be around 12–13 years.

Figure 7 is also the AP view of the elbow joint. Here the three centres (capitulum, trochlea and lateral epicondyle) have united to form a conjoint epiphysis (> 13) but it has not yet joined with shaft (< 15). Thus the opinion given regarding the age was between 13 and 15 years.

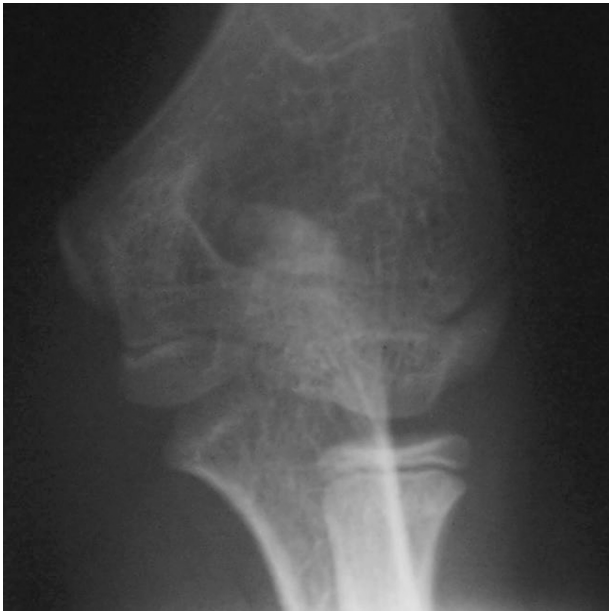

Fig. 6 X-ray of the elbow showing all four centres (medial epicondyle, capitulum, trochlea and lateral epicondyle) separately. This indicates that the age is around 12–13 years.

Ossification around wrist joint

The wrist joint presents quite a number of bones for radiological analysis. This is one of the reasons many workers regard this as the single most important region for the estimation of age (Greulich & Pyle, 1959). Other advantages stem from the small amount of irradiation required and the ease of radiographic positioning (Roche et al. 1988).

The lower end of the radius appears at around 2 years and that of the ulna around 6 years. Both unite with the shaft between 15 and 17 years in females and 17 and 20 years in males. The order of appearance of ossification centres in the carpal bones is as follows: capitate 2–4 months; hamate 3–5 months; triquetrum 1–3 years; lunate 3–4 years; scaphoid, trapezium and trapezoid 4–6 years; and pisiform 8–10 years. These ages can be remembered by the simple illustration shown in Fig. 8.

Metacarpals show more variation in time of appearance and fusion than the major long bones of the limbs. Reasonable estimates can be deduced from the base of first metacarpal (thumb), which unites by 16 years.

Figure 9 is the AP view of the wrist joint of a female who had undertaken voluntary sexual intercourse with her boyfriend. The question was whether she was below the age of consent (16 years). Sexual intercourse with a girl below the age of consent, even with her consent, is considered statutory rape. As her 1st metacarpal was not united, the opinion was that she was less than 16 years of age. This was corroborated by other findings.

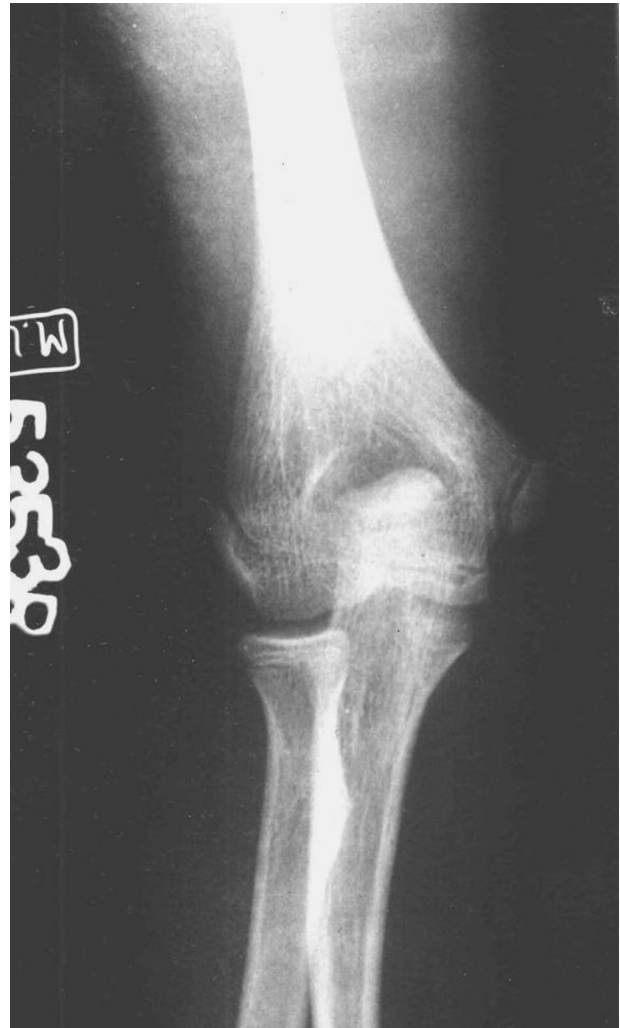

Fig. 7 AP view of the elbow joint. The capitulum, trochlea and lateral epicondyle have united to form a conjoint epiphysis, but it has not yet joined with the shaft.

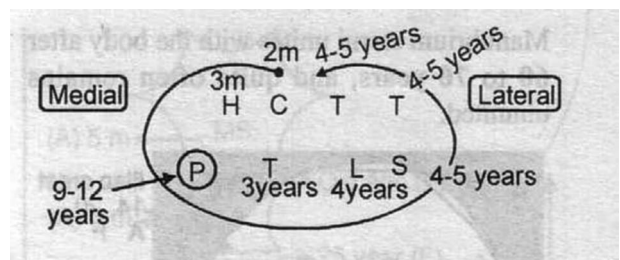


Fig. 8 A simple illustration to remember ages of ossification of carpal bones.

Ossification in the sternum

This bone is quite often neglected by medico-legal practitioners, but good corroborative use can be made of its maturity in relation to age estimation. The sternum consists of three parts – the manubrium, the body of the sternum and the xiphoid process. The body of the sternum is

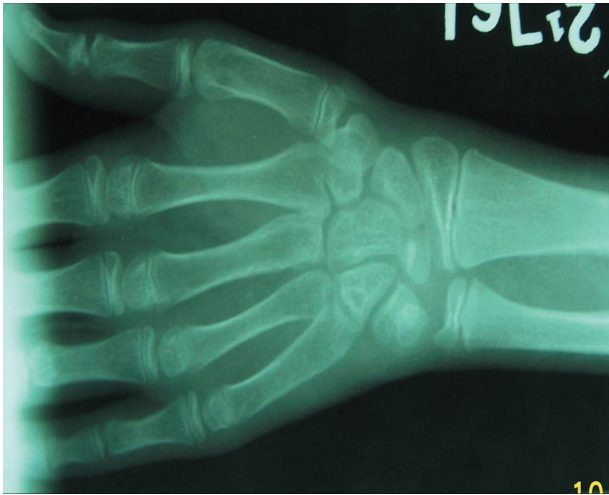

Fig. 9 Pisiform, the last carpal bone to ossify has appeared, indicating that the age is above 12 years. The epiphysis of the 1st metacarpal has not united, indicating that the age is less than 16 years.

made up of four sternebrae. The centres for the manubrium sterni and the sternebrae appear during fetal life and are of limited importance from a medico-legal angle (as far as estimation of age in the living is concerned). The centre for the xiphoid process generally appears at around 3 years of age, but can show considerable variation. The union of the four sternebrae occurs from below upwards. The figures which this author has used with success are: union of 3rd and 4th sternebrae at 4–10 years; union of the 2nd and 3rd at 11–16 years, and union of the 1st and 2nd at 15–20 years. The xiphoid process often unites with the body after 40 years. The manubrium can unite with the body after 60–70 years but often remains separate.

Figure 10 shows the lateral view of the sternum of an 18-year-old male and Fig. 11 is a line diagram depicting the same view. The subject was referred to the author by a civil court for an age certificate as he wanted to marry his girlfriend in court (their parents had not consented to the marriage) and he could not produce an age certificate. He asserted that he was 22 years of age (this would legally enable him to marry). A dental and radiological examination conclusively proved that he was around 18 years of age. The lateral view of the sternum corroborated this view. The 3rd and 4th sternebrae had united (> 15 years), but not the 2nd or 3rd (< 20 years). A significant space can be seen between the manubrium and the 1st sternebrae, as well as between the 1st and 2nd sternebrae.

Ossification around the hip joint and pelvis

The region around the hip joint and pelvis is probably the third most useful joint for age estimation after the wrist and elbow joints. The ischiopubic ramus usually unites by 7–8 years. The iliac crest appears at around 14 years of age and unites with the ilium by 23 years. The centre at the tip of the pubis appears at 14 years and at the tip of ischium

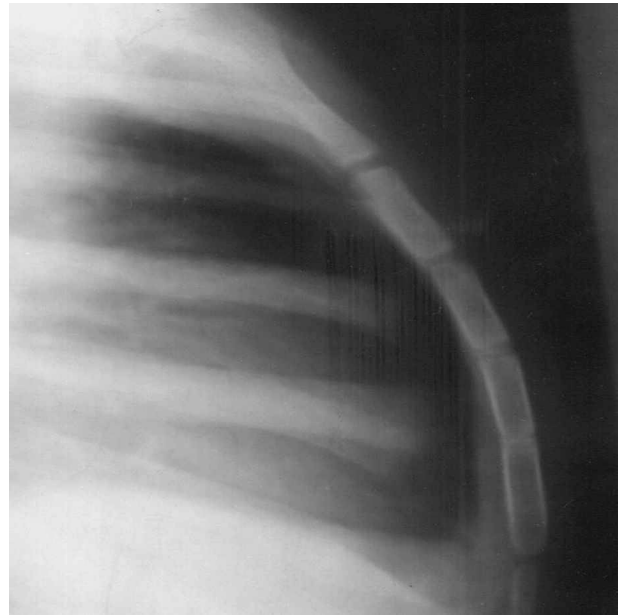

Fig. 10 Lateral view of the sternum of an 18-year-old male. Please note that while the 3rd and 4th sternebrae have united, the 2nd and 3rd, and the 1st and 2nd sternebrae have not.

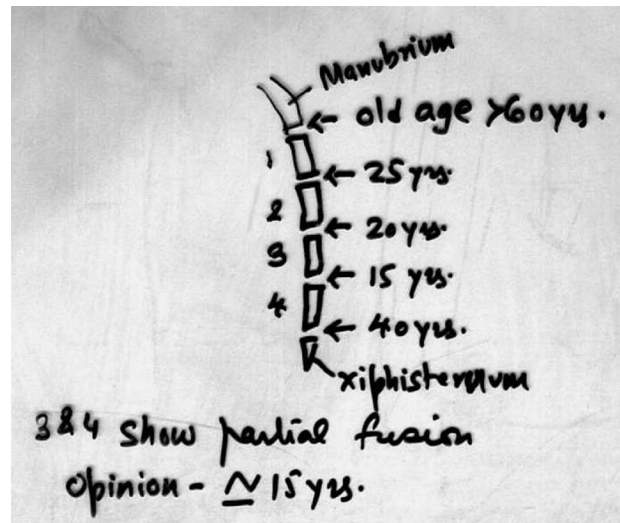


Fig. 11 A line diagram of the same X-ray as shown in Fig. 10.

by 16 years. These two centres unite with the rest of the bone by around 20 years. Ossification in the acetabulum occurs via a complex route which relies on a co-ordination between ossification in the triradiate cartilage and via separate epiphyses, which help to form the mature acetabular rim. Ossification in the triradiate cartilage becomes visible radiographically by 13 years and will have completed ossification and fused by 15 years.

The head of the femur appears by 1 year, the greater trochanter by 4 years and the lesser trochanter by 7–12 years. All these centres unite with the shaft by 18 years.

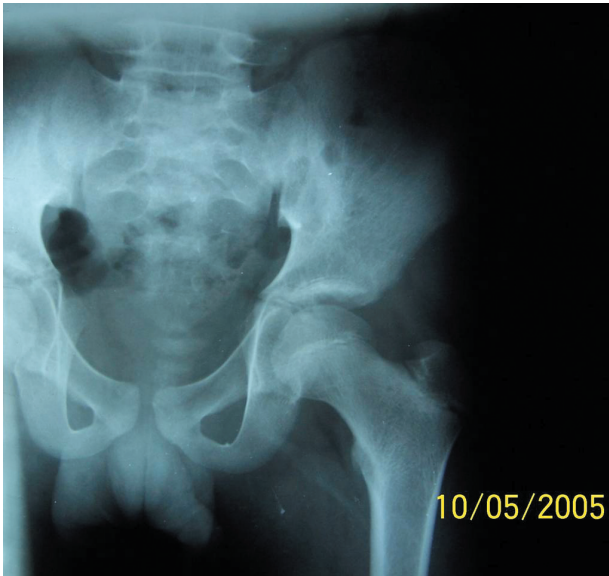

Fig. 12 X-ray of the hip joint of a 13-year-old male. Note that iliac crest has not appeared, triradiate cartilage is still visible, and the greater trochanter has not united with the shaft.

Figure 12 is an AP view of both hip joints of a 13-year-old male who was referred to this author as he had claimed eligibility for entry to a children's home on the basis of being below 18 years of age. The centre for the iliac crest had not appeared (< 14 years). Triradiate cartilage could be seen (< 15 years), and the greater trochanter had not united with the shaft (< 18 years). A combination of these findings enabled us to tell that the age of the subject was likely to be less than 14 years.

Figure 13 depicts the X-ray of the hip joint of a 2.5-year-old male child whose parents had divorced and the question was the legal custody of the child. According to the prevalent law in India, normally a minor who has not attained the age of 5 years shall remain in the custody of the mother. In this case the father had claimed that the child was older than 5 years and he should be in his custody – a claim contested by the child's mother. The X-ray showed that the head of femur had appeared (> 1 year), but the greater trochanter had not (age < 4 years). Clearly the child was below 5 years. From other criteria we could deduce that the child was about 2.5 years of age.

Figure 14 shows the X-ray of a young child less than 1 year of age who had won first prize in a baby show intended only for children less than 1 year of age. The cash prize was rather large, and it was claimed by several other parents that the child who eventually won the prize was related to the organizers and that is why they allowed a child older than 1 year to compete. The X-ray showed that the lower end of the femur had appeared (> 9 m intrauterine life). The upper end of the tibia can be seen faintly (it appears just at birth). The upper end of femur had not

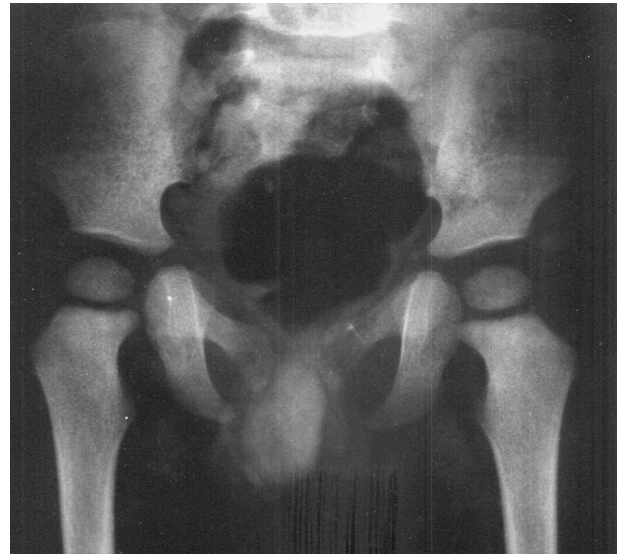

Fig. 13 X-ray of the hip joint of a 2.5-year-old male child. Note that the head of the femur has appeared, but the centre for the greater trochanter has not.

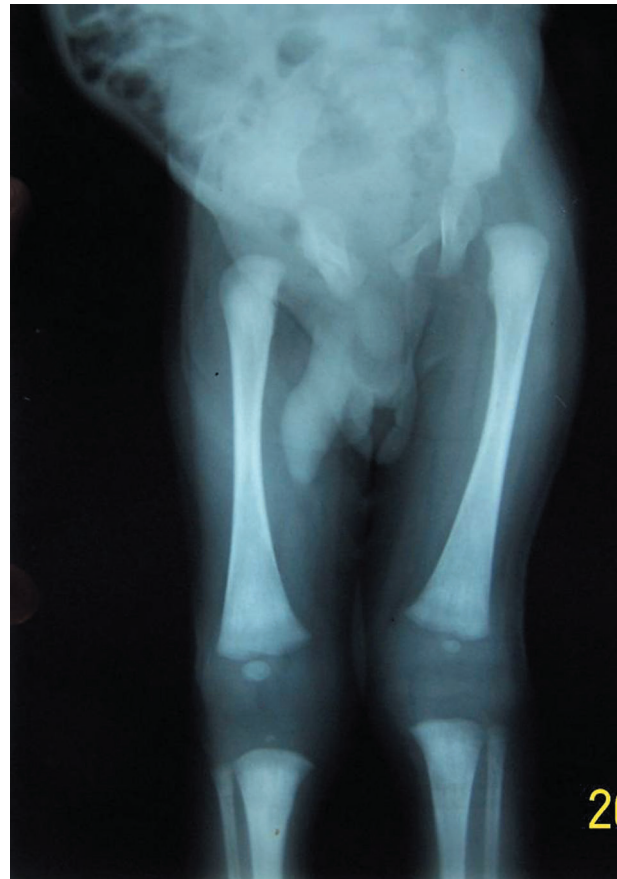


Fig. 14 X-ray of the hip joint of a male child less than 1 year of age. Please see text for details.

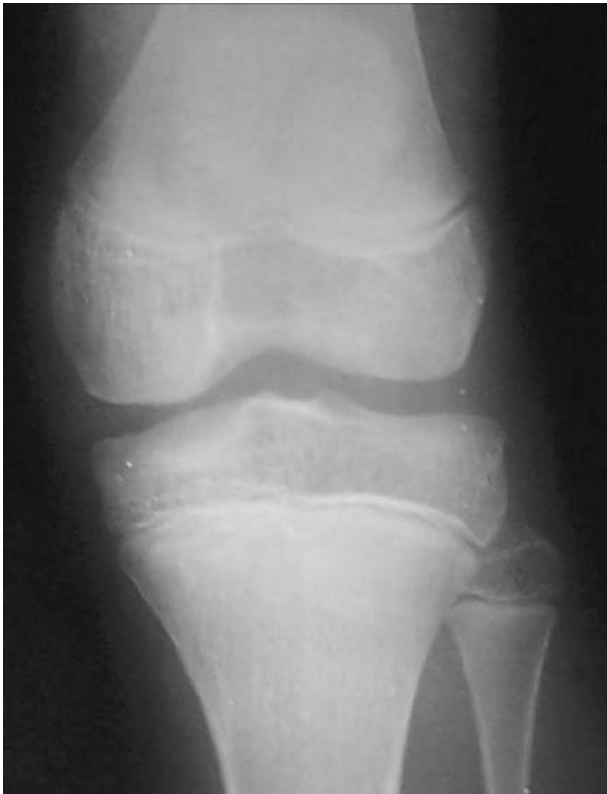

Fig. 15 X-ray of the knee joint of a male less than 18 years of age. Please see text for details.

appeared (< 1 year). The upper end of the fibula had also not appeared (< 4 year). Taking all these findings into consideration, we suggested that the child was indeed less than 1 year of age.

Ossification around the knee joint

The centre for the lower end of femur appears around the 9th month of intrauterine life. The centre in the upper end of the tibia appears at around birth and in the upper end of the fibula at around 4 years. All three centres unite with their respective shafts by 20 years.

Figure 15 is the AP view of the left knee joint of a male younger than 18 years who was caught snatching a bag from a lady. He claimed entry to a juvenile home on account of being younger than 18 years, a fact which was contested by the police. The X-ray of his knee showed that the lower end of the femur and the upper ends of the tibia and fibula had not united, supporting his statement of being younger than 18 years.

Ossification around the ankle joint

The centre for the lower ends of both the tibia and fibula appear during the first year of life and unite with their respective shafts by 18 years. The primary centre for the calcaneus appears in the 5th month of intrauterine life and its secondary centre by 6 years. It unites by 16 years.

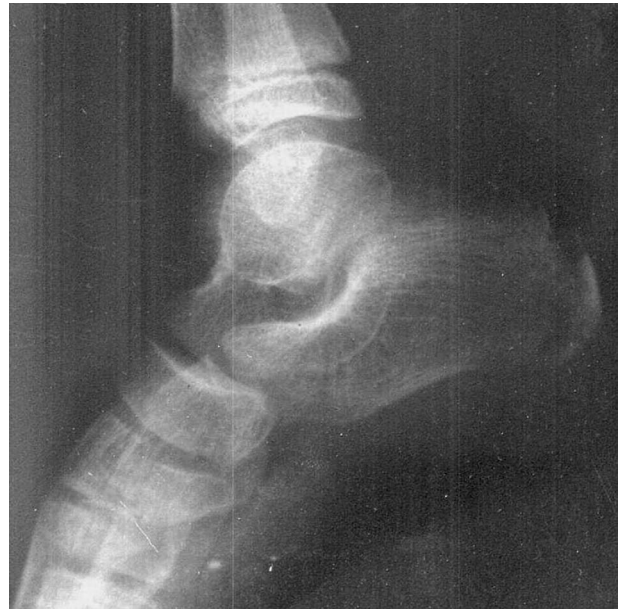

Fig. 16 X-ray of the ankle joint of a 8½-year-old child. Please see text for details.

Figure 16 shows the X-ray of an 8-year-old male who was caught stealing some coal from railway wagons. His lawyer claimed that he was less than 7 years of age and thus was not legally responsible for his crime. The X-ray of the ankle showed that the secondary centre in the calcaneum had appeared (> 6 years), but had not united (< 14 years). Thus just from one X-ray the author could say that the child was between 6 and 14 years of age. Other criteria including teeth helped estimate his actual age at around 8½ years.

Inputs from other specialties

Paediatricians have been using some interesting methods for calculating skeletal age for quite some time. They compare the bone age with the chronological age of the children for diagnosing several disorders, which show a characteristic relation between the two. For instance, hormonal deficiencies, notably those of thyroid and growth hormones, usually cause a bone age retardation of as much as 3 years or more. Most chronic disorders that impair growth because of metabolic causes or as a consequence of undernutrition will result in a bone age retardation of approximately 2 years. In contrast, certain conditions can accelerate bone growth so that it exceeds chronological age, e.g. thyrotoxicosis, sexual precocity and, to a lesser extent, simple exogenous obesity.

As far as this author is aware, these methods have not been used for medico-legal estimation of age, but there is no reason why they should not be taken into consideration.

Most of these methods referred to in this communication thus far can be divided into two broad groups. In one group – the atlas method – an atlas is used to compare the

radiographs of various joints and once the X-rays are exactly matched, the ages are read off directly from the atlas. In the other group – a scoring method – a scoring is undertaken for each bone in an X-ray according to some prescribed rules, and the final age is read off some tables. The leading method in the atlas group of methods is that of Pyle et al. (1971), and the undoubted leader of the other group is the method of Tanner & Whitehouse, often known as the TW II method. Tanner and colleagues developed this method in 1962 (Tanner et al. 1962), which was later modified in 1975 (Tanner et al. 1975). Consequently the first system came to be known as the TW 1 method and the second as TW II method (sometimes written as TW 1 and TW 2). The method of De Roo & Schröder (1976) falls into the first group, and the Fels method (Roche et al. 1988) into the second group. For details of these methods, the original publications must be consulted.

Several authors have tried to compare the accuracy and ease of use of these methods (Buckler, 1983; Milner et al. 1986; Cole et al. 1988; van Lenthe et al. 1998). The general consensus is that whereas the atlas methods, led by those of Greulich and Pyle, are easier to perform, the results are more accurate with scoring methods, led by those of Tanner and Whitehouse. Before an attempt is made to use these methods for medico-legal estimation of age, it must be remembered that the data for these methods were derived from children taken from a particular nation during a specific period of time, so the data may not work well for other nations, or even within different areas of the same nation. The method of Pyle, for instance, is based on an American population, and it is widely believed that this method does not give accurate results for British subjects. On the other hand, the method of Tanner and Whitehouse is based on British children.

Some authors have made an interesting attempt to adapt these well-established methods for their own needs in different ways. Cole et al. (1988) thought that the atlas of Greulich and Pyle did not give accurate results for the local population of Middlesbrough, UK, so they examined 200 hand radiographs of local children and after studying them thoroughly devised this interesting equation;

$$\text{Recalibrated GP age} = \text{Nominal GP age} \times 1.065 + 0.129$$

Nominal GP age refers to the age which Greulich and Pyle's atlas suggests and the recalibrated GP age refers to the age following adjustment. The authors showed that this formula gave more accurate ages for their own population. This method can be kept in mind by prospective workers wanting to use these methods for their own population.

Secondary sex characters

Secondary sex characters only give a very vague idea of the age and are obviously not very helpful from a medico-legal

Table 6 Tanner's stages of penile, scrotal and testes development and their corresponding ages

Stage 1 (G1): Testes, scrotum, penis are small sized. No rugosities in scrotum. Testicular volume 4–5 cm ⁻¹ each. [9–10 years].
Stage 2 (G2): Skin of scrotum reddens and changes in texture (slight rugation). Enlargement of penis, scrotum and testes. Testicular volume 6–7 cm ⁻¹ . [10–11 years].
Stage 3 (G3): Further growth of penis (at first mainly in length but with some increase in breadth), scrotum and testes. Testicular volume 15 cm ⁻¹ . [12 years].
Stage 4 (G4): Scrotal skin darkens. Glans develops. Further enlargement of penis, scrotum and testes. Testicular volume 20 cm ⁻¹ . [13–14 years].
Stage 5 (G5): Genitalia adult in size and shape. Testicular volume 25–30 cm ⁻¹ . [15–16 years].

angle. But sometimes they can provide good corroborative evidence. Hair first appears around the pubes, then in the axilla and finally over the face. In the male, fine downy hair begins to appear around the pubes by 14 years and in the axilla by 15 years, and on the chin and upper lip at between 16 to 18 years. The colour of the hair becomes darker, and they become somewhat thicker in a couple of years. Hair on the inner sides of the thigh and on the scrotum may appear after 18 years. The Adam's apple becomes more prominent by 16–18 years.

Penile and scrotal development as described by Tanner (1962) are also helpful. He described their development in five distinct stages and related them with age. The changes in scrotum, testes and penis, and their corresponding ages as described by Tanner are as given in Table 6.

Testicular volumes can be measured by orchidometers, ultrasonography or simply by measuring length and width of testes. The required formula is (Daniel et al. 1982):

$$\pi/6 \times L \times W^2$$

where L and W represent the length and width of testis, respectively, testis being regarded as an ellipsoid.

Secondary sex characters are helpful in females, too. Onset of menstruation varies greatly from person to person and from population to population. Thus medico-legal specialists dealing with age estimation should collect data from their own region before embarking upon the task of medico-legal age estimation. In Indian females, menstruation starts typically by 12–13 years, breasts begin to develop by about 13 years, and fine downy hair appears on the mons veneris by about 13 years. They become thicker and darker in about a couple of years.

In the UK, these ages are typically less, but as mentioned earlier, it would be best to collect data first from the population among which the medico-legal specialist is working. Estimation of age from such well-researched data would also stand the scrutiny of courts much better.

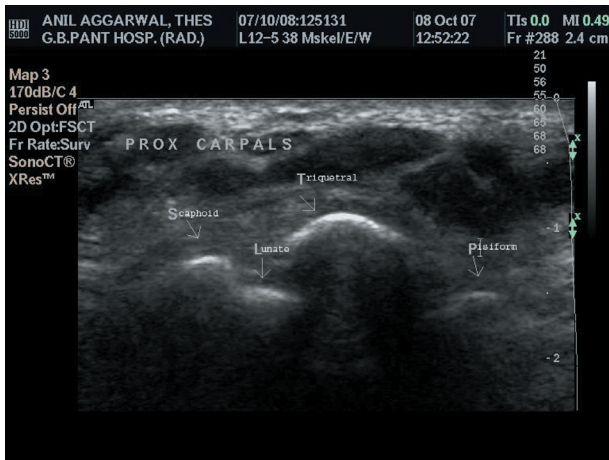


Fig. 17 Ultrasound of the right wrist of the author (52 years). All proximal carpal bones can be seen.

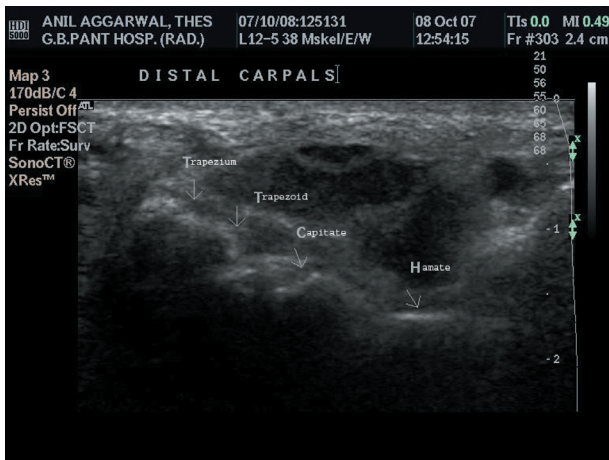


Fig. 18 Ultrasound of the right wrist of the author. All distal carpal bones can be seen.

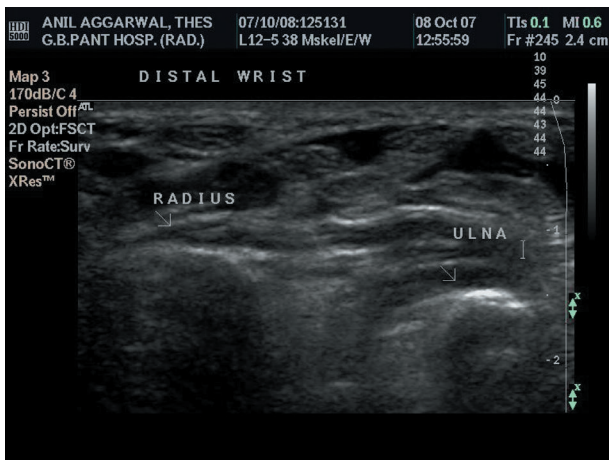


Fig. 19 Ultrasound of the right wrist of the author. Lower ends of both radius and ulna have appeared and united.

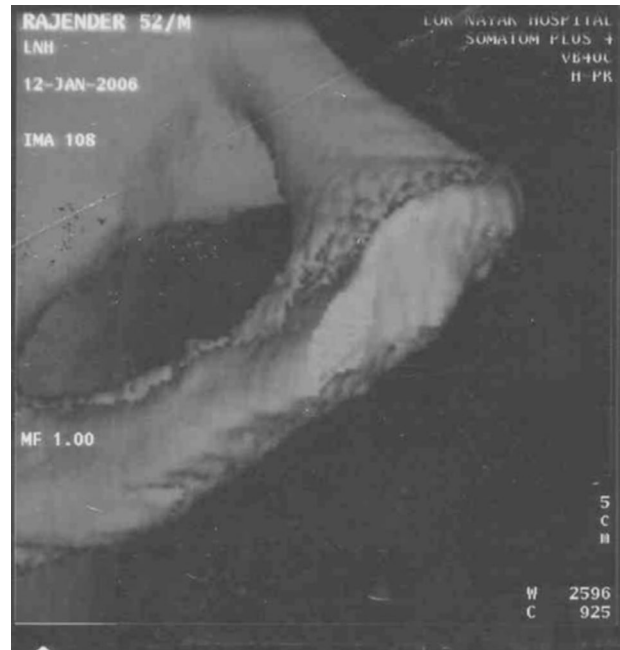

Fig. 20 CT of pubic symphysis 3D SSD (surface shaded display) with slices of 1 mm. The subject is above 50 years of age, which can be assessed from the partial loss of rugosities of the symphyseal surface.

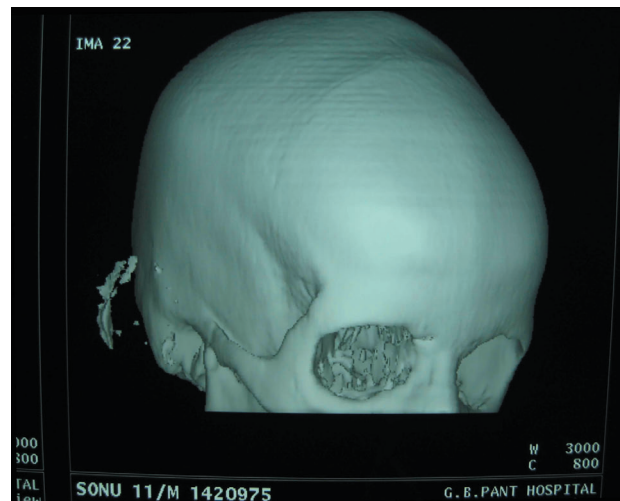

Fig. 21 Spiral CT of the skull of an 11-year-old male. Note that none of the cranial sutures has united.

Table 7 Estimation of age by cranial suture closure

Suture	Commencement	Halfway closed	Termination
Spheno-occipital synchondrosis	–	–	20
Coronal suture	25	30	40
Sagittal suture	25	30	40
Lambdoid suture	25	30	45
Pterion	40	–	65
Masto-occipital suture	45	–	80
Asterion	–	–	50

MAULANA AZAD MEDICAL COLLEGE, NEW DELHI
DEPARTMENT OF FORENSIC MEDICINE
AGE ESTIMATION REPORT

5002/50/05

No. FM/08/APP/FM Conducted by Dr. Anil Aggrawal
 Date 29/11/2005 Time 2:00 pm
 Name Sunita s/o Dr. J. J. Colony s/o Dr. J. J. Colony
 R/o g-339 J.J. Colony, Gurgaon, Haryana
 Age (as told by patient) 15 yrs (Mother's)
 Onset of Menarche (Females) 22 yrs (Father's)
 Brought by Mother
 Referred by Hon. J. J. Colony
 FIR No./D.D.No. None
 Alleged history of Case of father's heavy exposure
 Year back claim have been given to children
 These cases are related to the father's case in all variance
 Consent: with her appearance In the opinion of the honorable
 I consent s/o Dr. J. J. Colony
 R/o Dr. J. J. Colony
 give my free consent for a complete medical examination and other relevant investigations for the purpose of making an age report. The nature and consequences of such examination have been explained to me. In token thereof I subscribe my signature /thumb impression herewith.

Signature of witness Mother LTI Anil Aggrawal
 Signature/thumb impression Mother

Marks of Identification :

1. Black coloured, non-hairy, raised mole on (L) side of the lip, 1 cm below ala of nose.
2. Pinhead non-hairy, brown mole present on (L) side of neck 5 cm below (L) mastoid process.

General Physical Examination:

Built-Good/Average/Poor
 Height 131 cms, Weight 25 kg, Pulse 88/mi
 HAIR:
 Pubic not appeared Axillary not appeared
 Beard not appeared Moustache not appeared
 Breast Development not developed
 Genital development not developed

Dental Examination
 Oro-dental hygiene Good
 Dental formula:

\times 17 16 15 14 13 12 11 | 21 22 23 24 25 26 27 \times
 \times 47 46 45 44 43 42 41 | 31 32 33 34 35 36 37 \times

S indicates Space behind 2nd molar,
 X indicates tooth not erupted or space not present.

Radiological Examination
 X-ray plates 2175 dt. 30.11.2005
 Findings:

1) Upper end of tibia & fibula not united < 10 yrs.
 2) Lower end of tibia & fibula not united < 17 yrs.
 3) Pisiform appeared > 12 yrs.
 4) Iliac crest appeared > 14 yrs.
 5) Cuneiform appeared but not united with shaft < 15 yrs.

OPINION: In my opinion, based on physical, dental and radiological findings, when taken together, the age of the person examined is between 14 and 15 years.

(Dr. Anil Aggrawal)
 (Dr. Anil Aggrawal)

10/05/2005

Figs 24 and 25 Front and back of a typical age report.

Estimation of age in older persons

Estimation of age after 25 years poses a real challenge, as by that time all teeth have erupted and most bones have united, thereby achieving full maturity. Closure of skull sutures helps to some extent here. In general the skull sutures close in the pattern shown in Table 7.

An antero-posterior (Towne) view of the skull must be used to visualize all major sutures. This view readily shows the sagittal, coronal and lambdoid sutures. The same sutures can also be seen in postero-anterior radiographs of the skull. Both these X-rays must be advised, as different sutures may be seen clearly in different positions, although it is recognised that the taking of such radiographs on the living may pose some serious ethical considerations and would not be permitted in many countries.

The basisphenoid suture is visible in the submento-vertical radiograph of the skull. An X-ray of the lumbar and cervical spine often shows lipping of the vertebrae and the appearance of osteophytes after the age of 40 years. A chest X-ray may show ossification of costal cartilages.

As earlier stated, X-rays of the sternum may be of some use after the age of 40 years. X-rays of the neck may be

tried to see the ossification of the thyroid and laryngeal cartilage as well as the union of the greater cornu of the hyoid with its body. Again, such axial radiographs pose significant ethical issues for most countries.

The author has utilised these radiographic views for estimating the age of older individuals.

Features such as the arcus senilis (> 40 years), hair in the auditory meatus (> 50 years), greying of hair (> 40 years), loss of scalp hair (> 40 years), appearance of cataracts (> 50 years) and falling out of teeth (> 60 years) are too variable to be of any use from a medico-legal angle, although they can offer supporting evidence.

Newer methods

Newer imaging methods have recently been applied for estimation of age. Leading contenders in this area are imaging by ultrasound (Castriota-Scanderbeg et al. 1998; Bilgili et al. 2003; Schulz et al. 2008) (Figs 17–19), echocardiography (Belozerova 2006) and computed tomography (Schulze et al. 2006; Yang et al. 2006) (Figs 20 and 21).

Estimation of age in actual practice

Estimation of age is usually undertaken at the request of the police for criminal cases, but in some exceptional cases

it is also performed in civil cases. An employer may contest the age of his employees, asserting that they are older than they claim and that they are not fit for the job because of their advancing age. Such a scenario is more common when a smaller company is absorbed by a larger company. The management of the larger company may want to dispense with the older employees and may claim that the age of the employees is greater. In a recent case, a smaller company Indo Burma Petroleum (IBP) was taken over by the Indian Oil Corporation (IOC). The Indian Oil Corporation then claimed that the ages of several IBP workers were not correct. Nine such employees were sent to the author for assessment of their age (Fig. 22).

The usual procedure is to undertake a thorough physical and dental examination, after which X-rays are requested from the radiologist. Figure 23 shows a typical X-ray form filled in for the purpose of age estimation. The important points to note are that two identification marks are mentioned at the top. A picture is also affixed to the X-ray form. This is to ensure that the subject is not 'switched' when he/she is transferred to the X-ray unit, which in a large hospital is often quite a distance from the forensic medicine department. The radiologist then ensures that it is the same subject by matching the photograph and the identification marks.

After the X-rays are received, all data is reviewed once again and a final report is prepared to be handed over to the police or to other proper authorities. Figures 24 and 25 show a typical age report.

The report typically consists of three parts – the preliminaries, the main body of the report and the opinion. All the preliminaries are self evident from Fig. 24. An important practical point is to obtain the consent of the individual. According to law, any physical examination of an individual without his consent may amount to assault. However, if the patient is arrested (criminal investigation), the consent may not be necessary (Aggrawal & Busuttill, 1991).

It is important to note that an opinion is given only after careful consideration of all parameters – general physical development, dental eruptions and ossification of bones. The author is tempted to say in the end that estimation of age is probably a judicious mix of fine art, rigorous science, careful judgment and shrewd intuition. This art can only be learnt with practice. No amount of rote learning without practice is going to be of any help, and experience with one's own population is essential as data may not be directly translatable from one population to another. This is a vital consideration if the medico-legal investigator is requested to assist in matters of immigration and asylum.

References

- Aggrawal A (2000) Age estimation in the living – some medicolegal considerations. *Anil Aggrawal's Internet Journal of Forensic Medicine and Toxicology* [serial online], Vol. 1, No. 2 (July–December 2000): [about 23 p]. Available from: http://www.geracds.com/anil/ij/vol_001_no_002/ug001.html. Published: July 1, 2000 [accessed 1 September 2008].
- Aggrawal A, Busuttill A (1991) Age estimation in the living. *Police Surg (J Assoc Police Surg)* **38**, 33–36.
- Belozerova LM (2006) Biological age estimation using echocardiography [In Russian]. *Adv Gerontol* **19**, 90–92.
- Bilgili Y, Hizel S, Kara SA, Sanli C, Erdal HH, Altinok D (2003) Accuracy of skeletal age assessment in children from birth to 6 years of age with the ultrasonographic version of the Greulich-Pyle atlas. *J Ultrasound Med* **22**, 683–690.
- Brand RW, Isselhard DE (1986) *Anatomy of Orofacial Structures*. London: C. V. Mosby Company.
- Buckler JMH (1983) How to make the most of bone ages. *Arch Dis Childhood* **58**, 761–763.
- Cameron JM, Sims BG (1974) *Forensic Dentistry*, p. 25. Edinburgh: Churchill Livingstone.
- Castriota-Scanderbeg A, Sacco MC, Emberti-Gialloreti L, Fraracci L (1998) Skeletal age assessment in children and young adults: comparison between a newly developed sonographic method and conventional methods. *Skeletal Radiol* **27**, 271–277.
- Cole AJ, Webb L, Cole TJ (1988) Bone age estimation: a comparison of methods. *Br J Radiol* **61**, 683–686.
- Daniel WA Jr, Feinstein RA, Howard-Peebles P, Baxley WD (1982) Testicular volumes of adolescents. *J Pediatr* **101**, 1010–1012.
- De Roo T, Schröder HJ (1976) *Pocket Atlas of Skeletal Age*. The Hague: Martinus Nijhoff Medical Division.
- Greulich WW, Pyle SI (1959) *Radiographic Atlas of Skeletal Development of the Hand and Wrist*, 2nd edn. Stanford, CA: Stanford University Press.
- Jit I, Kulkarni M (1976) Times of appearance and fusion of epiphysis at the medial end of the clavicle. *Ind J Med Res* **64**, 773–782.
- Mason R, Bourne S (1998) *A Guide to Dental Radiography*. Oxford: Oxford University Press.
- Milner GR, Levick RK, Kay R (1986) Assessment of bone age: a comparison of the Greulich and Pyle, and the Tanner and Whitehouse methods. *Clin Radiol* **37**, 119–121.
- Osborn JW (ed.) (1981) *Dental Anatomy and Embryology*, pp. 144–151. Oxford: Blackwell Scientific Publications.
- Pyle SI, Waterhouse AM, Greulich WW (1971) *A Radiographic Standard of Reference for the Growing Hand and Wrist*. Chicago: Press of Case Western University (Yearbook Medical Publishers).
- Roche AF, Chumlea W, Thissen D (1988) *Assessing the Skeletal Maturity of the Hand-wrist: Fels Method*. Springfield, IL: Charles C Thomas.
- Rogers, SL (1988) *The Testimony of Teeth*. Springfield, IL: Charles C. Thomas.
- Schulz R, Zwiesigk P, Schiborr M, Schmidt S, Schmelting A (2008) Ultrasound studies on the time course of clavicular ossification. *Int J Legal Med* **122**, 163–167.
- Schulze D, Rother U, Fuhrmann A, Richel S, Faulmann G, Heiland M (2006) Correlation of age and ossification of the medial clavicular epiphysis using computed tomography. *Forensic Sci Int* **158**, 184–189.
- Tanner JM (1962) *Growth at Adolescence*, 2nd edn. Oxford: Blackwell Scientific Publications.
- Tanner JM, Whitehouse RH, Healy MJR (1962) *A New System for Estimating Skeletal Maturity from Hand and Wrist, with Standards Derived from a Study of 2600 Healthy British Children*. Paris: Centre International de l'Enfance.
- Tanner JM, Whitehouse RH, Marshall WA, Healy MJR, Goldstein H (1975) *Assessment of Skeletal maturity and Prediction of Adult Height (TW 2 method)*. London: Academic Press.

van Lenthe FJ, Kemper HCG, van Mechelen W (1998) Skeletal maturation in adolescence: a comparison between the Tanner-Whitehouse II and the Fels method. *Eur J Pediatr* **157**, 798–801.

Williams PL, Warwick R (1980) *Gray's Anatomy*, 36th edn. Edinburgh: Churchill Livingstone.

Woelfel JB, Scheid RC (1997) *Dental Anatomy – Its Relevance to Dentistry*, 5th edn. Baltimore: Williams & Wilkins.

Yang F, Jacobs R, Willems G (2006) Dental age estimation through volume matching of teeth imaged by cone-beam CT. *Forensic Sci Int* **159** (Suppl. 1), S78–83.